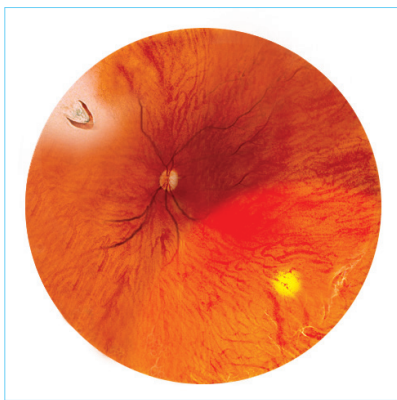


Who Are at Risk of Retinal Detachment?

1. Middle-aged persons with PVD which causes retinal tear
2. Eyes with retinal lattice degenerations, atrophic holes or horse-shoe tears
3. High myopes (higher than -6.0 Dioptres)
4. Ocular or orbital trauma
5. Previous intraocular surgery (e.g. cataract or glaucoma surgery)
6. Certain inherited diseases (e.g. Marfan's Syndrome, Stickler's Disease)
7. Family history of retinal detachment
8. Diabetic retinopathy
9. Retinopathy of prematurity, etc

Regular Eye Examinations Can Preserve Vision

Please schedule regular eye examinations with your ophthalmologist.



Peripheral retinal degeneration and retinal tear

For enquiries and appointments, please contact us at:

Department of Ophthalmology

4/F, Li Shu Fan Block
Hong Kong Sanatorium & Hospital
2 Village Road, Happy Valley, Hong Kong

Tel: 2835 8880 / 2835 8890

Fax: 2892 7510

Email: eye@hksh-hospital.com

Service Hours (By appointment only)

Monday to Friday: 9:00 am – 5:00 pm

Saturday: 9:00 am – 1:00 pm

Closed on Sundays and Public Holidays

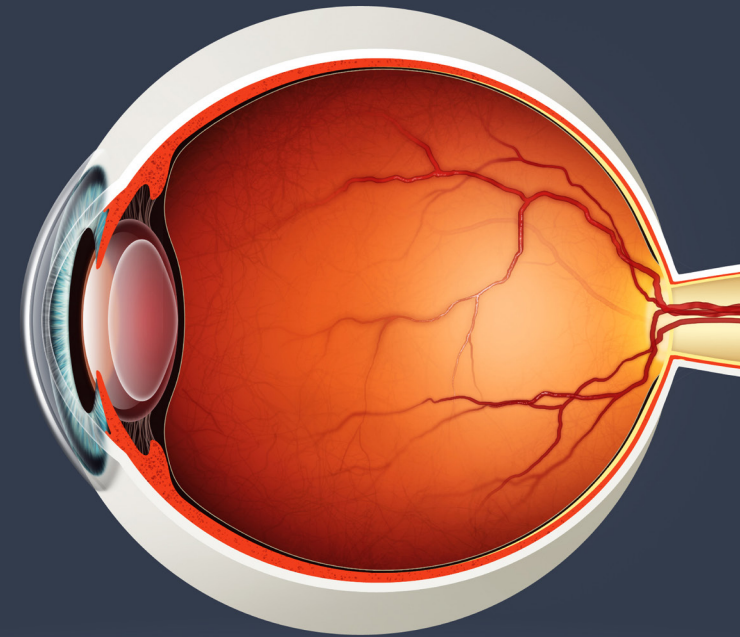
www.hksh-hospital.com

© Hong Kong Sanatorium & Hospital Limited. All rights reserved.

眼科部

Department of Ophthalmology

Floaters & Retinal Detachment

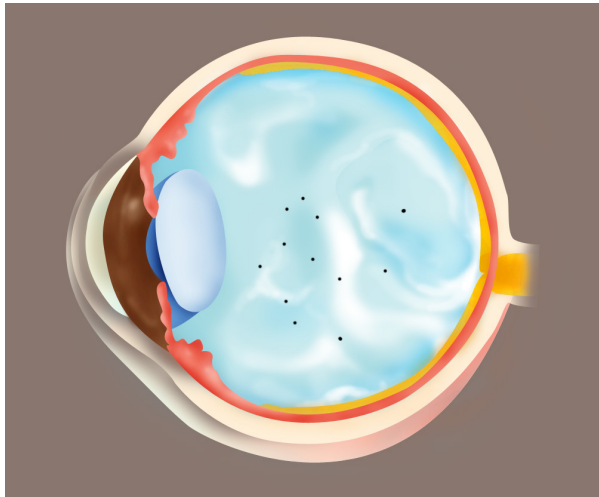


養和醫院
Hong Kong Sanatorium & Hospital

眼科部

Department of Ophthalmology

OPH-1111/H/E-04-1/2015



Vitreous degeneration and floaters

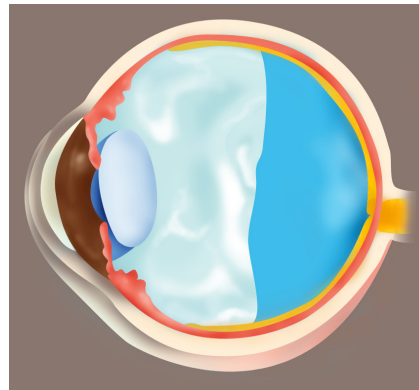
What Are Floaters?

The jelly-like substance filling the space between the crystalline lens and the retina is called “vitreous humour”. The vitreous humour degenerates and liquefies when we get older, at which time we start to see floaters. Floaters can be moving opacities of various shapes and sizes (dots, circles, lines or spider webs). Physiological floaters usually occur when we are looking at a bright homogenous background such as a white wall or the blue sky. The floating opacities are few in number and remain unchanged over time. They represent normal physiological changes of the vitreous humour.

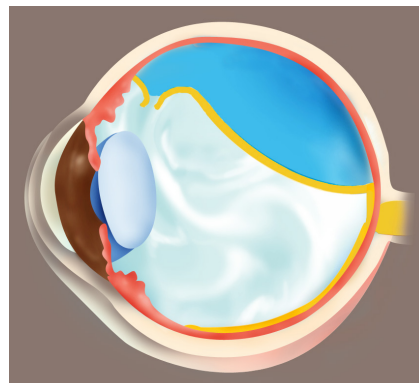
Pathological floaters appear suddenly and may occur in great numbers. They may suggest bleeding within the vitreous humour, inflammation of the uvea or separation of the posterior vitreous humour from the retina. If the floaters are accompanied by flashes or visual field defects, it may indicate retinal tear or retinal detachment. An ophthalmologist should be consulted immediately to distinguish the causes of these conditions.

Flashes, Acute Posterior Vitreous Detachment and Retinal Detachment

As we age, the vitreous humour undergoes the processes of synchysis (liquefying) and syneresis (dehydrating and shrinking). These are normal age-related degenerations. When the vitreous humour contracts and detaches from the retina, it is called acute posterior vitreous detachment (acute PVD), at which time sudden onset of floaters and flashes occur. Floaters can be caused by vitreous opacities or haemorrhages, whereas flashes are caused by the vitreous humour pulling on the retina. An urgent dilated eye examination is essential to check for retinal tears, which should be repaired with laser as soon as possible, to prevent it from evolving into retinal detachment within a few hours.



Posterior vitreous detachment



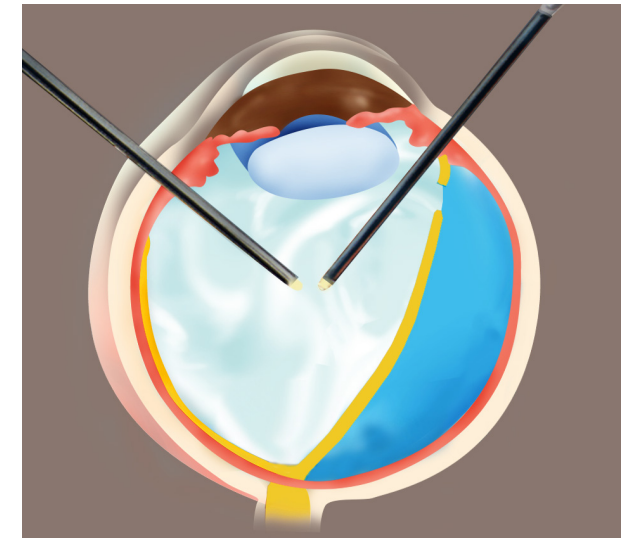
Retinal tear and detachment

What Are the Symptoms of Retinal Detachment?

1. Increased floaters
2. Increased flashes
3. Visual field loss
4. Visual distortion or disturbance

Treatment for Retinal Detachment

Retinal degenerations or tears can be repaired with laser while retinal detachment is treated with surgery. There are two main types of retinal detachment surgery, namely scleral buckle, which is performed around and outside the eyeball, and vitrectomy (with gas or silicone oil injection), which is performed inside the eyeball. Both of the surgeries include laser treatment or cryotherapy.



Vitrectomy